

Joye M. Carter, M.D., FCAP  
Chief Medical Examiner



(713) 796-9292  
(713) 796-6815  
FAX: (713) 796-6842

OFFICE OF THE MEDICAL EXAMINER OF HARRIS COUNTY  
JOSEPH A. JACHIMCZYK FORENSIC CENTER  
1885 OLD SPANISH TRAIL  
HOUSTON, TEXAS 77054-2098

AUTOPSY REPORT

OC 99 - 2

January 3, 1999

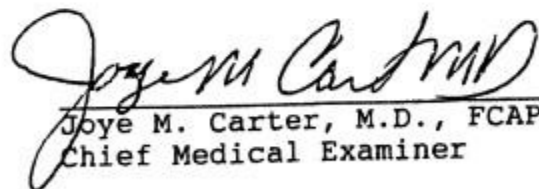
ON THE BODY OF

Melissa Trotter  
7201 F.M. 3081  
Willis, Texas

CAUSE OF DEATH: Asphyxia due to ligature  
strangulation.

MANNER OF DEATH: Homicide.

Reviewed and signed by:

 11 Jan 99  
Joye M. Carter, M.D., FCAP Date  
Chief Medical Examiner

## POSTMORTEM EXAMINATION ON THE BODY OF

Melissa Trotter  
7201 F.M. 3081  
Willis, Texas

**HISTORY:** The body of an unidentified Caucasian female, subsequently identified as that of 19 year old Melissa Trotter, was found January 2, 1999, in the National Forest of Montgomery County, Texas. The body was received at the Harris County Medical Examiners Office for postmortem examination and identification. The sealed body bag was opened at 12:35 p.m. on January 3, 1999, by Mr. Reynolds, Harris County Medical Examiner's Forensic Scientist, in the presence of Dr. Joye M. Carter, Chief Medical Examiner. Prior to autopsy examination, trace evidence was collected and the missing persons report filed on behalf of Melissa Trotter was reviewed, dental records of Melissa Trotter were reviewed, and medical records of Melissa Trotter were reviewed. Total body X-rays were obtained and reviewed. A sexual assault kit was performed.

**IN ATTENDANCE AT THE AUTOPSY:** Mr. David Tanner and Detective Brian M. DuBose, Montgomery County Sheriff's Office; Mr. Mike McDougal, District Attorney's Office, Montgomery County; Dr. DeLattre and Dr. Stimson; Autopsy Assistant, Mr. Michael Jones; and Forensic Photographer, Ms. Marlene Suarez.

**AUTOPSY:** The autopsy was performed in the Joseph A. Jachimczyk Forensic Center of Harris County by Chief Medical Examiner Joye M. Carter, M.D., at the request and upon the written authorization of The Honorable John R. Kleimann, Justice of the Peace, Precinct 1, Montgomery County, Texas, beginning at 2:15 p.m., on January 3, 1999.

**CLOTHING:** The body was received clad in blue denim jeans, white socks, one black and white gym shoe on the left foot. The sole of the gym shoe, with treads, was clean with minimal debris noted. There was no caked mud or grass observed on the bottom of the shoe. On the top of the body was a green, long-sleeved, over-sweater which zipped in front with burgundy and white stripes at the elbows. Beneath this sweater was a long-sleeved black sweater and a bra which had been pushed up over the breasts. Beneath the blue denim jeans were red underpants. No personal effects were received with the body. Prior to examination, fingernail scrapings were performed and fingerprints were taken. During fingerprinting, the skin and nails of the right hand removed in a glove formation secondary to decomposition. The outer green sweater and black sweater underneath were cut open with evidence tape along the cut edges marked for further examination. The body was then undressed for further examination. Removed from the front

right pocket was a piece of lined paper with the number 409-524-3008 and the name "Nicole" handwritten. This information was retrieved for evidence collection. The socks were removed by cutting and removal from the feet which revealed an unusual patterned red and green nail polish. The denim jeans were cut in the front to ease removal. The cut edges were marked with "HC" (Harris County) in red permanent ink. Upon removal, the denim jeans label on the inside read size 5, tapered leg, slim fit, medium length, Number 10912 Levi's. The rear pockets of the jeans contained no paper or other objects. The right rear pocket area was remarkable for an irregular rip which was 11 by 6 by 5-1/2 inches, encompassing the right rear pocket. The long-sleeved black sweater's inside label read "Sweater Exchange, 100% cotton, size small." The overtop, which was green and long sleeved, had an inside label which read "Energie, size medium." The undergarments consisted of a white bra which was fastened in the back; and red, thong-type underpants. The inside label of the bra read "Fruit of the Loom, size 36B." The inside label of the underpants read "size 6."

EVIDENCE OF MEDICAL INTERVENTION: None.

EXTERNAL APPEARANCE: The body received was that of a young Caucasian female whose facial appearance was distorted due to decompositional change characterized by skin slipping, greenish-black discoloration of the facial skin, and marbling of the skin of the legs, arms, chest, and back. The body was damp due to external weather conditions. The body had a length of 63 inches and a weight of 113 pounds with clothes on. The nude body had a weight of 105 pounds. At the time of autopsy examination, rigor had passed and livor was obscured due to decompositional change. The body was cool and damp to the touch. The head was normocephalic and covered by long reddish-brown hair, approximately 12 to 15 inches in length. The scalp hair was slipping due to decompositional change. There were no palpable skull or facial bone fractures. The scalp skin was intact with no evidence of laceration. The ocular globes were liquefied. Iride color was not discernible. The facial skin appeared to have been removed due to decompositional change and postmortem insect and animal activity. Upon reflecting the residual soft tissue around the right eye, rodent teeth impressions were identified. The nasal cartilage was intact. Soft tissue was absent from the nose and midfacial areas. Dentition was natural and in good condition. There were 28 teeth present. The tongue was protruding and dark black in color due to decompositional change. The oral cavity contained fly larvae. The buccal mucosa was not present. The alveolar ridges were not hypertrophic. Both ears were markedly discolored due to decompositional change. There was a single pierced hole of each earlobe. The neck was remarkable for a brown stocking ligature which was tied in the back in a simple knot. There was a 3 by

2-3/4 inch defect on the anterior neck with liquefaction of tissue, maggot activity, and blood present. The anterior chest with breasts and the abdominal contour were remarkable only for decompositional change. There were no palpable masses or scars appreciated. There were no tattoos present. The external genitalia were those of an adult female. The body hair was female in distribution. The upper extremities were symmetrical and well formed and were remarkable for decompositional change. There were no tattoos, venous track marks, or unusual scars of the upper extremities. The fingernails were remarkable for a green-and-red-striped fingernail polish. There was marked skin slippage of the skin of the right hand with only the fingernail remaining on the 2nd digit. The skin of the left hand was intact but was too moist for fingerprinting. The lower extremities were symmetrical, well formed, and remarkable for decompositional change. The dorsum of the left foot was remarkable for a 3 inch curvilinear, hyperpigmented scar which was well healed. The toenails of both feet were remarkable for the same patterned red and green nail polish. The posterior surface was remarkable for plant vegetation adherent to the body. There was no discreet pattern of livor mortis. The anal and vaginal orifices were unremarkable with the exception of decompositional changes. The skin of the body diffusely showed splotchy areas of red, green, and gray discoloration secondary to postmortem mold growth. There was generalized skin slippage with discoloration and marbling over the entire body surface.

**INTERNAL EXAMINATION:** Section: The thoracoabdominal region was explored using an H-shaped incision. The sternum and rib cage were intact. The midline fatty subcutaneous tissue at the level of the umbilicus was 1/2 inch in depth. The right hemithoracic cavity contained approximately 150 cubic centimeters of sanguineous fluid. The left hemithoracic cavity contained approximately 100 cubic centimeters of sanguineous fluid. The pericardial sac was intact and contained approximately 10 cubic centimeters of sanguineous fluid. The peritoneal cavity contained a minimal amount of sanguineous fluid. All organs maintained their usual anatomic relationships. The appendix was observed, as was the gallbladder. There appeared to be no previous intervening surgical procedure through the skin of the abdominal or chest wall. The breast tissue was firm and intact. There were no appreciable masses upon serial sectioning of the fibrofatty tissue of the breasts.

**HEART:** The heart was intact with a residual weight of 175 grams. The external epicardial surface was dull tan-brown. The heart had a normal configuration and a flabby consistency. There was minimal subepicardial fatty tissue deposition noted on both anterior and posterior surfaces. The coronary arteries arose normally in the aortic root. The vessels were widely patent and contained no evidence of narrowing due to atheromatous plaque buildup. The

aorta was intact with a smooth intimal surface and had minimal fatty streaking along its entire length. The myocardium was red-brown in appearance, dull, and homogeneous with noted decompositional change. There was extreme laxity of the consistency due to decompositional change. The heart valves were dark in color and thin with no evidence of malformation. The endocardial surface was dull and tan-gray. The aorta was intact and remarkable for decompositional change.

**LUNGS:** The right lung weighed a residual 325 grams while the left weighed 450 grams. The pleural aspects were red-brown, somewhat mottled, and glistening in appearance. Upon sectioning, the pulmonary arterial tree bilaterally was patent with no evidence of thromboemboli. There was no evidence of vascular malformation. The bronchial tree was dissected bilaterally. There was no obstruction by mucus plug, foreign body, or insect activity. The pulmonary parenchyma bilaterally was markedly congested. There were no palpable areas of consolidation. There was no apparent anthracotic pigment deposition due to the decompositional state and the dark burgundy-purple discoloration of the parenchyma.

**LIVER:** The liver had a residual weight of 775 grams. The capsular surface was intact and dull gray-brown. The anterior margin was sharp and the parenchyma had a soft consistency. Upon sectioning, the parenchyma was red-brown and dull in appearance. It appeared to be homogeneous with no evidence of preexisting tumor mass or infectious disease process. There was no nodularity upon serial sectioning of the hepatic parenchyma. The gallbladder bed was intact and contained approximately 5 cubic centimeters of thin brown bile. The bile passages were patent. There was no evidence of cholelithiasis. The gallbladder mucosa was yellow-green and velvety in appearance.

**Pancreas:** The pancreas was intact with a residual weight of 100 grams. The external surface was dark red-brown and dull due to decomposition and autolysis. There was loss of the normal tissue architecture with very limited lobulation noted. Upon sectioning, the duct was patent. The cut surface was yellow-red and autolyzed.

**Adrenals:** The left and right adrenal glands were markedly autolyzed.

**SPLEEN:** The spleen was intact with a weight of 100 grams. The capsular surface was red-brown, dull, and smooth. There were no defects noted to the hilar region. The entire spleen was retained for toxicological analysis. There were no areas of lymphadenopathy observed.

**GENITOURINARY TRACT:** The right and left kidneys each weighed 50 grams. The renal capsules stripped with ease to reveal dull red-brown, smooth cortical surfaces. Both kidneys had a flabby consistency. Upon sectioning, normal tissue architectural change was obscured due to decompositional change. The medullary regions were demarcated and appeared darker in coloration. The collecting systems were unremarkable. The proximal ureters were not dilated or obstructed. The urinary bladder was void of urine. The vaginal tract was lined by a thick tan-brown material. The approximate amount was 5 to 8 cubic centimeters. Upon rinsing, the vaginal wall displayed focal areas of pink-red discoloration. The internal genitalia were remarkable for mild decomposition change. The cervical os was examined and was circular with focal areas consistent with preexisting surgical manipulation of the endocervical surface. The uterus was nongravid and measured 2-3/4 by 2 inches in area. Both right and left ovaries were observed with their respective fallopian tubes. The left ovary contained a hemorrhagic cyst. The right ovary was unremarkable upon sectioning. Upon sectioning the uterus, the endometrial contents were a small amount of tan mucoid material.

**GASTROINTESTINAL TRACT:** The esophagus was intact and remarkable for decompositional change. The esophageal mucosa was purple-tan. The esophageal gastric junction was free of laceration. The gastric contents were approximately 200 cubic centimeters of poorly-masticated tan liquid in which large pieces of white meat, consistent with chicken, and pieces of potato, consistent with french fries, were observed. There were small portions of what appeared to be yellow and green vegetables, as well. There was no tablet or pill residue observed in the gastric contents. The pyloric region was patent. The first part of the duodenum contained a moderate amount of pink-tan chyme material. There was no evidence of ulceration of the proximal duodenum. The gastric mucosa, upon rinsing, displayed no evidence of ulceration. The rugal folds were normal in appearance. Decompositional changes were noted to the mucosal surface of the stomach. The remainder of the small and large intestine was intact and displayed mild to moderate decompositional change characterized by bubbling and transparency of the serosal surfaces. There were no foreign bodies within the rectal vault. The appendix was in its normal anatomic location and was unremarkable upon sectioning.

**NECK:** The neck region was explored initially. The skin was reflected laterally to reveal markedly decomposed anterior neck structures. There appeared to be a clean separation between the portion of larynx on the posterior aspect of the neck organs. The tongue was intact and was remarkable for a 1/2 inch intramuscular contusion on the right anterior aspect of the tip. The hyoid bone was palpated. It was flexible and was not fractured. The proximal portion of the thyroid cartilage was palpated and was intact. The

anterior edge of the thyroid cartilage appeared to be gnawed and irregular. The posterior segment of the larynx remnant was  $3/4$  inch in length by  $7/8$  inch. The inferior portion was smooth and dark brown. The remnants of the thyroid cartilage horns were irregular and appeared to be gnawed. The lower segment of the larynx measured  $3/4$  by  $3/4$  inch. The surface of the superior margin was remarkable for fine ridges. Opening the inferior segment of larynx revealed the left vocal fold to be intact. The right vocal fold was not identified. Upon reexamination, the inferior remnant of the larynx was irregular in the midline and there were tiny notched ridges from postmortem gnawing. The trachea was intact and the rings were not collapsed. There was no unusual material within the trachea. There was no foreign body or mucus plug. There were scattered maggots within the neck organs upon dissection. The aortic arch was dissected in proximity to the neck organs. The great vessels were given off normally. The great vessels in the proximate transection of the trachea had apparent teeth and gnaw marks. The thyroid gland was absent. The midportion of the larynx was absent. The cricoid cartilage was absent. The underlying cervical spine was intact with no palpable ridges from sharp force injury.

**HEAD:** The scalp was reflected forward via a bimastroid incision revealing no evidence of galeal or subgaleal hematoma. The calvarium was intact and free of fracture line. Upon removal of the calvarium, the dura mater was intact with no evidence of epidural hematoma formation. Upon removing the dura mater, there was no evidence of subdural hematoma formation. The brain had a residual weight of 1100 grams. There was no evidence of subarachnoid hematoma formation. Upon removal of the brain from the cranial cavity, the tissue was semiliquid and pink-green in color. There was complete loss of normal tissue architecture upon removing the brain tissue. There was no evidence of preexisting lesion or mass defect in the parenchyma. There was no evidence of ventricular abnormality. The vessels forming the circle of Willis were thin walled. The pituitary gland was markedly autolyzed. The basilar skull was free of fracture line. After examining the head, the jaws were incised and dental examination was obtained.

Total body X-rays revealed two metal screws in the metatarsal area of the left foot. There were no fractures to the skeletal system observed. Examination of the lower alveolar ridge revealed a retention appliance for orthodontic procedure.

**EVIDENCE OF INJURY:** Ligature Around the Neck: The ligature consisted of a piece of brown hosiery. The toe was intact on one limb of the ligature and it appeared to be a sandal-foot-type toe. The second limb appeared to be cut irregularly. The ligature was tied around the posterior surface of the neck. There was a single simple knot. The ligature was removed from around the neck by

cutting. The cut edges were marked with red identifying tape. The diameter of the ligature was 3-1/4 inches. The ligature appeared to be a cut leg of pantyhose. There was a 1/4 to 1/2 inch remnant of the panty portion on the cut end. The cut ends were slightly rolled. There was a run going through the entire length of the hosiery. The ligature imprint was poorly discernible due to the decompositional change of the neck. There was a dark purple, 2-1/2 inch, raised mark on the posterior surface of the neck. Upon inspection of the anterior neck wound, there appeared to be a transection of the larynx. The edges of the severed larynx were irregular due to postmortem animal activity. The surrounding tissue appeared to be hemorrhagic and dark secondary to postmortem insect and animal degradation. This was not discernible completely due to decompositional change.

**TOXICOLOGY:** Samples of heart fluid, chest fluid, bile, liver, gastric contents, and the entire spleen were retained for toxicological analysis. Also retained were samples of lung, kidney, brain tissue, and heart.

**HISTOLOGY:** Representative sections of all major organs were retained in formalin.

#### PATHOLOGICAL FINDINGS

1. Ligature around neck.
2. Decompositional change with maggot activity.

OFFICE OF THE MEDICAL EXAMINER OF HARRIS COUNTY  
JOSEPH A. JACHIMCZYK FORENSIC CENTER  
1885 OLD SPANISH TRAIL  
HOUSTON, TEXAS 77054-2098

REPORT OF ANALYSIS

January 13, 1999

TO: Joye M. Carter, M.D.  
Chief Medical Examiner

CASE#: OC99-002

Evidence submitted on 01/04/99.


RESULTS:


Blood: Ethanol- 0.06 g/dL  
Methanol, Acetone, Isopropanol- Not Detected.  
Norcarboxytetrahydrocannabinol- Not Detected.  
Delta-9-tetrahydrocannabinol- Not Detected.  
Standard Basic Drug Screen- Not Detected.  
Cocaine Metabolite, Amphetamine/Methamphetamine,  
Phencyclidine, Opiate- Not Detected.

Bile: Ethanol- 0.03 g/dL  
Methanol, Acetone, Isopropanol- Not Detected.

Liver: Ethanol- 0.02 g/g  
Methanol, Acetone, Isopropanol- Not Detected.

Unless otherwise requested, specimens will be discarded one year after date of receipt.

  
Patricia L. Small, B.S., MT, ASCP  
Assistant Toxicologist

  
Ashraf Mozayani, Ph.D., DABFT  
Chief Toxicologist

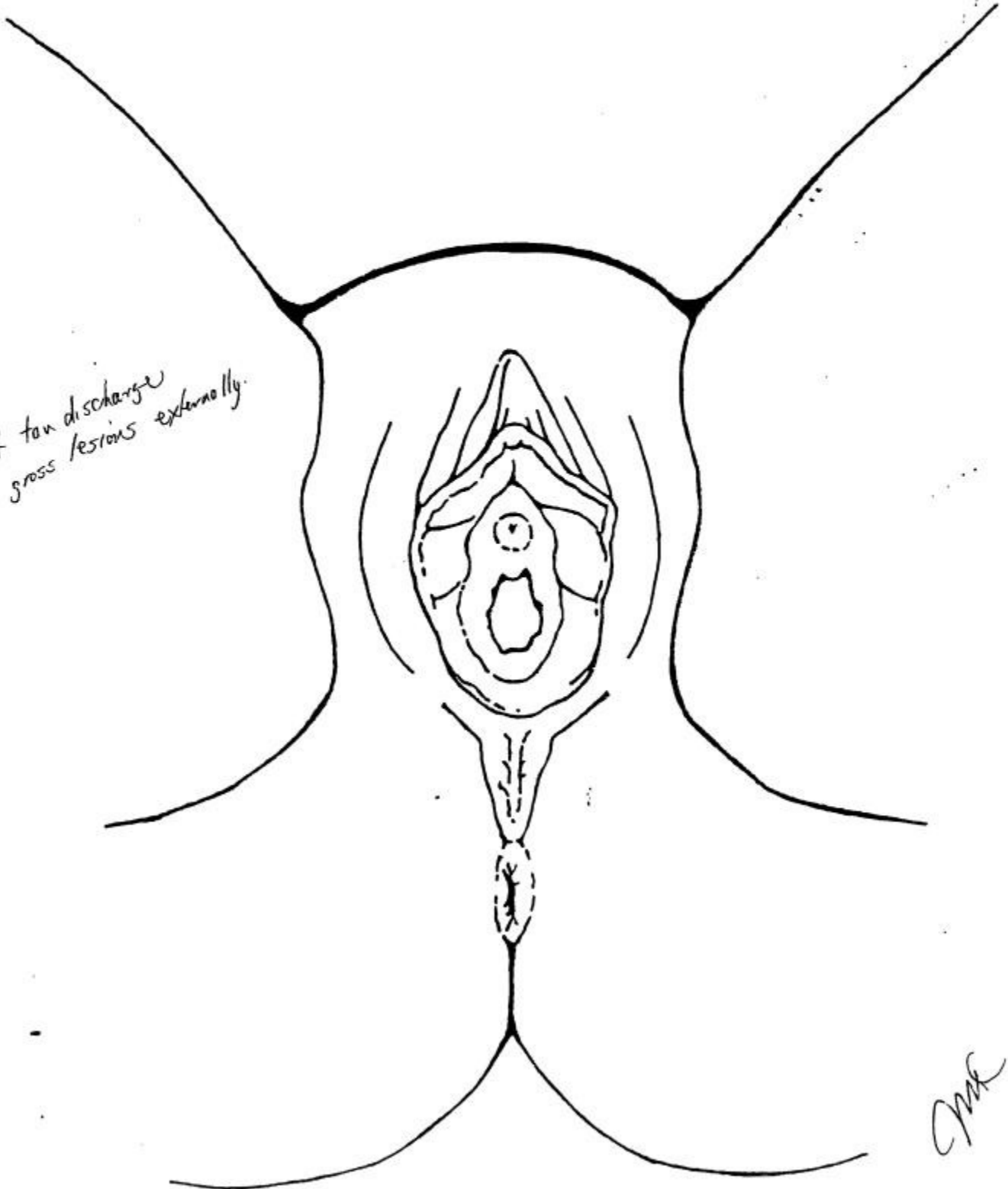Medical Examiner's Initial \_\_\_\_\_

PERINEUM, FEMALE

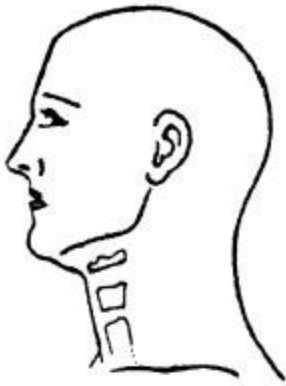Name Melissa Trotter

M.E. Case No. OC 99-002

- light tan discharge  
No gross lesions externally.

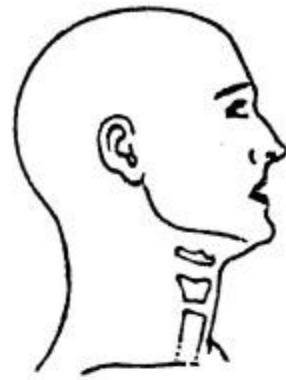


*Handwritten signature*

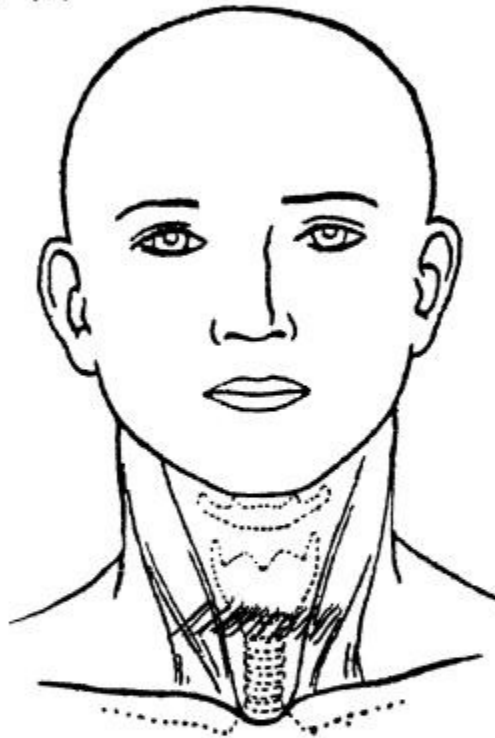


Head, Left Lateral (1)

EXTERNAL VIEWS  
OF THE HEAD

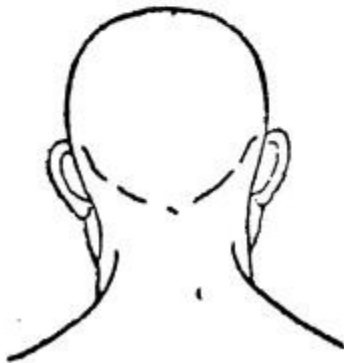


Head, Right Lateral (2)



Head, Anterior (3)

*Postmortem insect activity  
with defect in anterior neck area*



Head, Posterior (4)



Head, Superior (5)

*JMC*

skull: lateral, anterior, and posterior views.

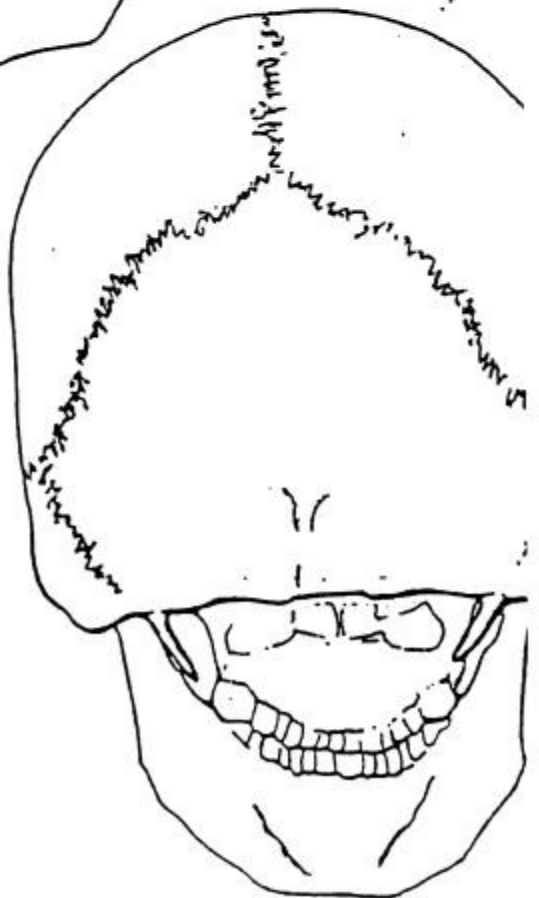
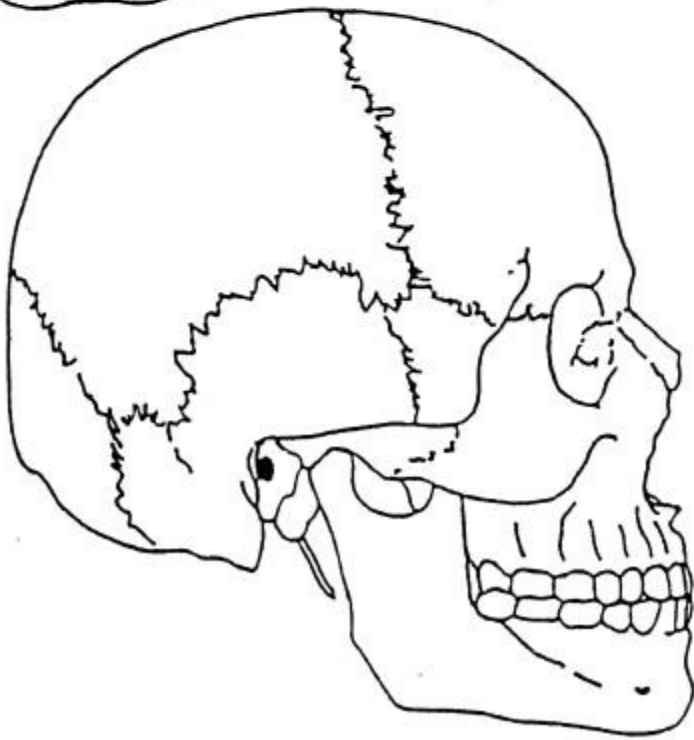
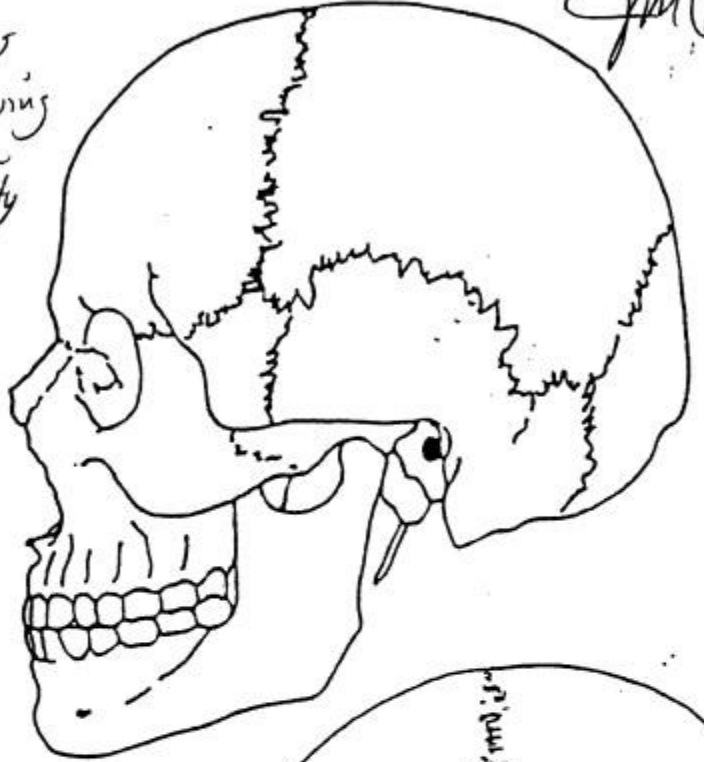
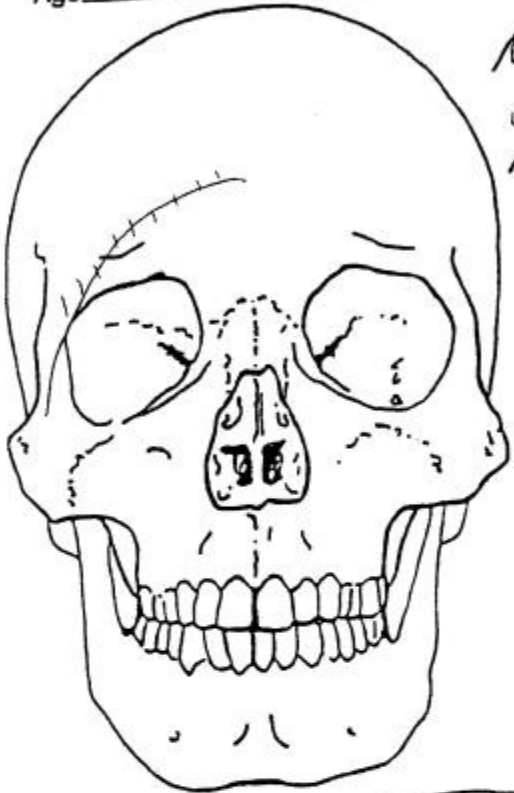
Melissa Trotter  
OC-99-002

Name \_\_\_\_\_ Medical Examiner Case Number \_\_\_\_\_

Age \_\_\_\_\_ Race \_\_\_\_\_ Sex \_\_\_\_\_ Date 01, 03, 99  
M D YR

JMC

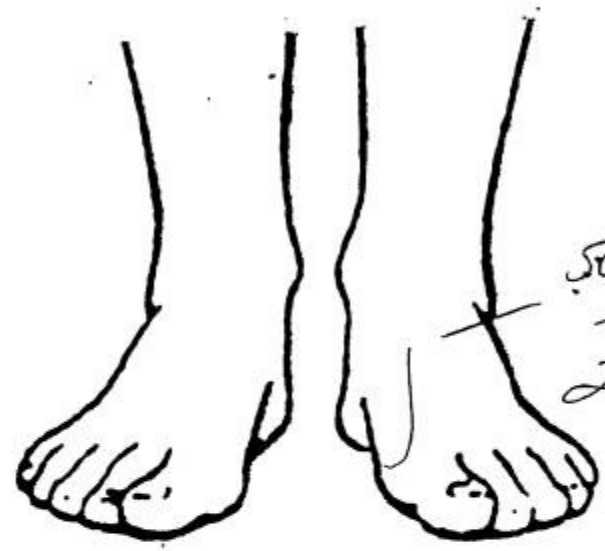
No fractures  
Slight gnawing  
marks from  
rodent activity



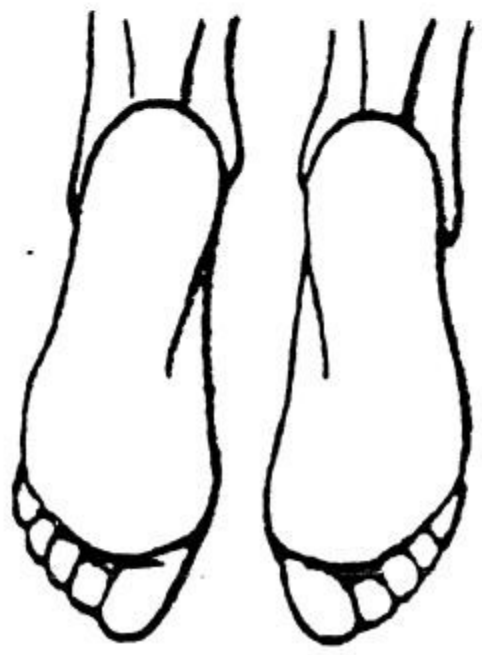
CASE NO. DC 99 002 NAME Melissa Trotter

AGE \_\_\_\_\_ RACE \_\_\_\_\_ SEX \_\_\_\_\_ HEIGHT \_\_\_\_\_ WEIGHT \_\_\_\_\_

Striped red and green  
nail polish



Scar on left  
foot  
2 sores viewed  
via Xray



JMC